Successful renal transplantation in **Muckle-Wells syndrome** treated with anti-IL-1β-monoclonal antibody

Associate Professor MD Aytan Mammadzada. Azerbaijan Medical University, Department of Internal Medicine I, Head of Nephrology department

PhD, MD Elnur Farajov. Mediland Hospital – Head of Nephrology department/Hemodialysis center

MD Nargiz Muradaliyeva. Azerbaijan Medical University, Nephrology department

Patient: Male

Year of birth: 1998

Normal pregnancy

Was born completely healthy

No complaints/concomitant diseases during early childhood

3 years old:

Episodes of pain in joints (elbows and knees)

Doctors expected acute rheumatic fever

Was prescribed regular penicillin injections (Bicillin-5:procaine benzylpenicillin+benzathine benzylpenicillin)

Was adviced more sunlight and heat

Improvement of symptoms

Hearing difficulties!

22 years old:

Measles

Fever up to 39–40°C

Characteristic rash

Diarrhea

Severe dehydration

Supportive treatment (restoring fluid balance)

After recovery:

joint pain and hearing problems intensified + temperature, up to 40°C, severe weakness, and swelling on the legs and face

Different doctors/different prescriptions (diuretics (mainly furosemid), methylprednisolone, and cyclosporine)

Elevated leukocytes in the full blood count

Episodes of severe joint pain, fever, and weakness

Consultation with a hematologist

Bone marrow aspiration from the sternum (Result – Normal)

Absence of any hematologic pathology

Elevated protein in the urine

Creatinine in the blood within normal limits

Consultation with a nephrologist

Was advised kidney biopsy, but refused

Alternative opinion

Traveled to Iran

Was advised kidney biopsy again, agreed

Renal amyloidosis

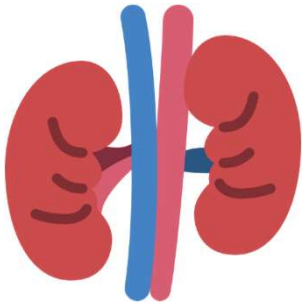

Microscopic Description

LIGHT MICROSCOPY:

Multiple sections are prepared and stained with H&E (3), Jones (x3), PAS (x3) and Congo red (x1).The biopsy consists of one piece of cortical tissue containing 19 glomeruli. 5 are globally sclerosed.

Most of the glomeruli show increased mesangial area filled with an acellular palely eosinophilic material that are not stained in silver stained sections and palely stained with PAS. Although silver stain show sun ray appearance in two gloms. Congo red stain reveal amyloid deposit showing green birefringence under polarized light. There are no crescent or fibrin in the Bowman's space. There are no endocapillary proliferation, or fibrinoid necrosis.

The tubules show vacuolar degeneration of their epithelial lining with atrophic changes about 60% specimen. The interstitium shows proportional fibrosis.

The arteriols are thick walled. Interlobular arteries show thickening and positive Congo red material of their wall. Large artery is not sampled.

IMMUNOFLUORSCENC MICROSCOPY:

Frozen sections each containing 3-4 glomeruli, are stained with IgG, IgA, IgM, C1q, C4, C3, Fibrinogen, Kappa, Lambda and polyvalent antisera. Casts are stained with IgA. All antisera are negative.

Diagnosis Kidney Percutaneous Biopsy:

Renal Amyloidosis

Comment All glomeruli in the specimen show increased mesangium and acellular pale eosinophilic material that stained orange to red in Congo red stain and show green birefringence under polarized light that is diagnostic for Amyloidosis. There's also some amyloid material in arteriolar and arterial wall. There is 60% tubular atrophy and interstitial fibrosis in favor of moderate to severe chronicity of the disease.

For definite differentiation between AL and AA type of amyloidosis IHC study is necessary. But more evaluation of the patient, such as bone marrow evaluation could also be helpful for definite diagnosis.

Resident: ----------

Pathologist: T.Pourlak, M.D. AP & CP

The biopsy consists of one piece of cortical tissue containing 19 glomeruli. 5 are globally sclerosed.

Diagnosis:

Renal Amyloidosis

Comment: All glomeruli in the specimen show increased mesangium and acellular pale eosinophilic material that stained orange to red in Congo red stain and show green birefringence under polarized light that is diagnostic for Amyloidosis. There's also some amyloid material in arteriolar and arterial wall. There is 60% tubular atrophy and interstitial fibrosis in favor of moderate to severe chronicity of the disease.

Biochemistry Continue

IgA		135.8	mg/dL	Immuno	70-400
C3		133.8	mg/dL	Immuno	90-180
C4		28.000	mg/dl	Immuno	10-40
Na		138	mEq/L	ISE	135 - 145
K		5.3	mEq/L	ISE	Adult: 3.5- 5.5
Calcium		8.8	mg/dl		13-60 years: 8.4-10.5
Phosphourus		4.7	mg/dL	Photo	Adult : 2.6-5
CRP	H	11.70	mg/L	Turbido	up to 6

?

Urine Biochemistry

Test	Risk	Result	Unit	Method	Normal Ranges
Urine Microalbumin (24 hrV1-V0)	H	14291*	mg/24 h	LC/MS/MS	< 28.8
Urine creatinine 24h (v1)		1.71	g/24 hrs	Photo	Femail : 0.6-1.8 Mail : 0.8-2.0 Child : 0.34-1.8
Urine Volume 24hrs(V1)		2400	mL		600-2500
Urine Protein (24 hr v0-v1)	H	21240*	mg/24 h	Photo	<150

* = Confirmed by Repeated Analysis

Urinanalysis

Urinanalysis

Macroscopy	
Color	Yellow
Appearance	Semi Clear
Specific gravity	1012
PH	6
Protein	Pos(2+)*
Glucose	Trace*
Ketones	Neg
Nitrite	Neg
Bilirubin	Neg
Urobilinogen	Neg
Blood	Neg

Microscopy	
WBC/hpf	6-7
RBC/hpf	2-3
EP/hpf	3-4
Bacteria/hpf	Few
Mucus	Neg

* = Confirmed by Repeated Analysis

Serology

Test	Risk	Result	Unit	Method	Normal Ranges
CryoGlobulins		Negative			Negative

Biochemistry

Test	Risk	Result	Unit	Method	Normal Ranges
FBS		83	mg/dL	Photo	13-60 years: 70-100
Urea	H	132	mg/dl	Photo	Adult: 12.8-43
BUN	H	62	mg/dl	Photo	Adult : 6-20
Creatinine	H	2.50	mg/dl	Photo	>=16 Year: 0.7-1.4
Uric Acid		6.6	mg/dL	Photo	Male : 3.6-8.2
Triglycerides		131	mg/dL	Photo	6-650 years: <200
Cholestrol	H	370	mg/dl	Photo	Normal <200 High >240
HDL	H	103	mg/dl	Photo	29 - 80
LDL	H	236	mg/dL	Photo	Adult Normal <130 Child Normal <110 Adult high risk >160 Child high risk >130
Albumin	L	3.0	g/dl	Photo	3.5 - 5.2
Alkaline phosphatase		124	U/L	Photo	80-306

Condition began to deteriorate and patient returned to Azerbaijan

Blood creatinine of 12 mg/dl

Urine protein more than 20g/day

Urticaria-like skin rash

Severe hearing impairment

Hemodialysis treatment

Was placed first with a temporary and then a permanent central venous catheter

Hemodialysis procedures were prescribed 3 times a week for 4 hours

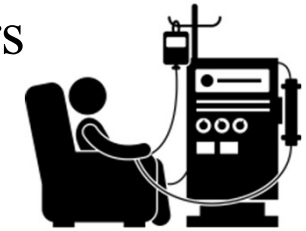

At the end of 2021, patient turned to our clinic

The most complete medical history was collected

Clinical manifestations were evaluated:

joint pain, urticaria-like rash, hearing impairment, increased protein in the urine, and increased creatinine in the blood

Presumptive diagnosis - Cryopyrin-associated periodic syndrome

We requested serum amyloid A

Amiloid A			
SAA (serum amiloid A)	741	H	0 - 6.4

CIAS1/NLRP3 gene pathology genetic test

Düzen Laboratuvarlar Grubu
"Uluslararası Kalite Güvencesi"

TÜRKAK

www.duzen.com.tr

GENETİK HASTALIKLAR TANI MERKEZİ

HASTA ADI SOYADI :	[redacted]	**ÖRNEK TİPİ :**	Periferik kan
YAŞ :	23	**KABUL TARİHİ :**	12.01.2022
PROTOKOL NO :	AMG-0090-22	**RAPOR TARİHİ :**	09.02.2022
ÖN TANI :	-	**İSTENEN TETKİK :**	*CIAS1* geni mutasyonları
KAYIT NO :	14696766	**GÖNDEREN MERKEZ :**	[redacted]

p.T350M (c.1049C>T) (rs151344629) mutation detected as heterozygous

CIAS1 GENİ DİZİ ANALİZİ
Yöntem: Genomik DNA Yeni Nesil Dizi Analizi,SeqPilot yazılımı
İncelenen Bölgeler: *CIAS1 /NLRP3* geni Ekzon 1-9
NCBI Genomik Referans Dizi: NG_007509.2, NM_004895.4

Hastalığa neden olan Mutasyon/lar:

p.T350M (c.1049C>T) (rs151344629) mutasyonu heterozigot olarak saptanmıştır.
Kodlayan dizinin 1049. pozisyonundaki sitozin nükleotidi timine dönüşmüştür. Bu değişim proteinin 350. pozisyonunda treonin aminoasidi yerine metionin amino asidi oluşumuna neden olmaktadır. **ClinVar** veritabanında belirtilen rs numarası *'Pathogenic'* olarak kayıtlıdır. Model analiz programı; bu değişimin klinik etkisi hakkında öngörüde bulunmaktadır. (Varsome: *Likely Pathogenic*), (Franklin: *Pathogenic*)

Muckle-Wells Syndrome

is a form of CAPS (Cryopyrin-associated periodic syndrome) that is caused by genetic mutations on the NLRP3 (CIAS1) gene that encodes the cryopyrin protein.

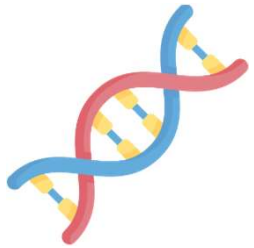

Spectrum of the inherited cryopyrin associated periodic syndromes (CAPS):

-Familial cold-induced autoinflammatory syndrome (FCAS)

-Muckle-Wells Syndrome

-Severe neonatal-onset multisystem inflammatory disease (NOMID) also known as chronic infantile neurologic, cutaneous, articular (CINCA) syndrome

DOI: 10.1002/acr.22206

MWS >>> mutations in the CIAS1/NALP3 gene >>> encodes the protein cryopyrin (danger sensors, called NLRs (NOD-like receptors)

When triggered by a danger signal >>> assembles with other molecules to coordinate an inflammatory response (“inflammasome”) >>> increased IL-1ß production

A mutation of the NLRP3 gene >>> cryopyrin inflammasome constantly overproduces IL-1ß >>> symptoms

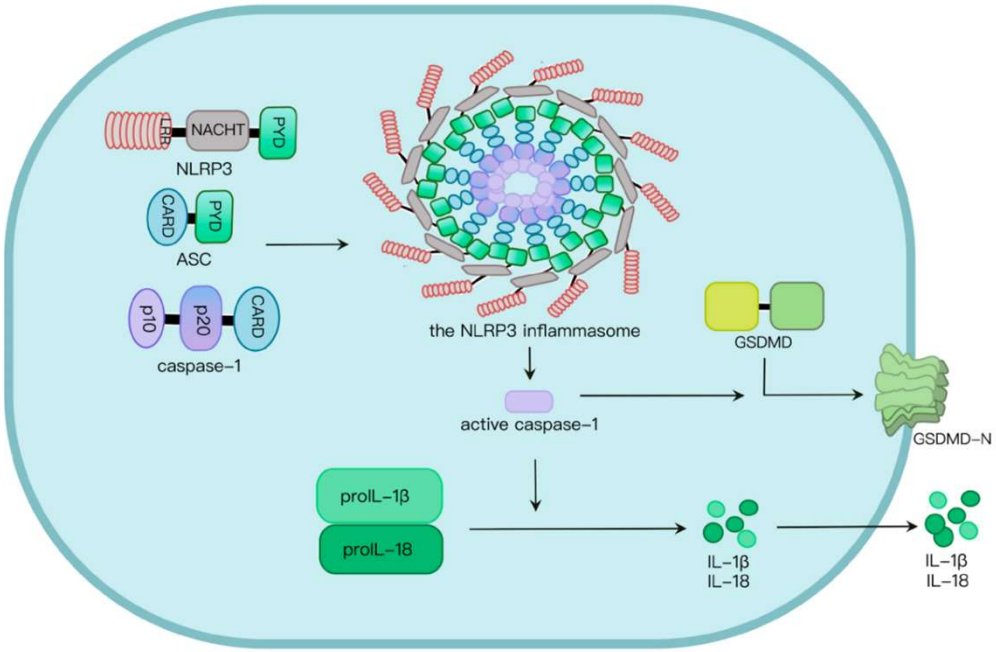

https://doi.org/10.3390/ijms24076126
DOI: 10.1002/acr.22206

Original description by Muckle and Well (1962) - triad of urticaria-like rash, deafness, and amyloidosis

Spectrum is constantly expanding: fever, fatigue, conjunctivitis, arthralgia, arthritis, myalgia, irritability, headache, abdominal pain, oral ulcers, pericarditis, and male hypofertility

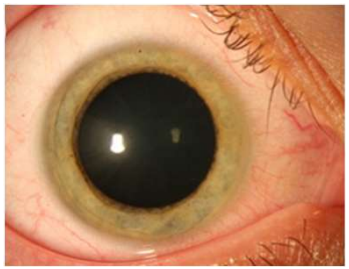

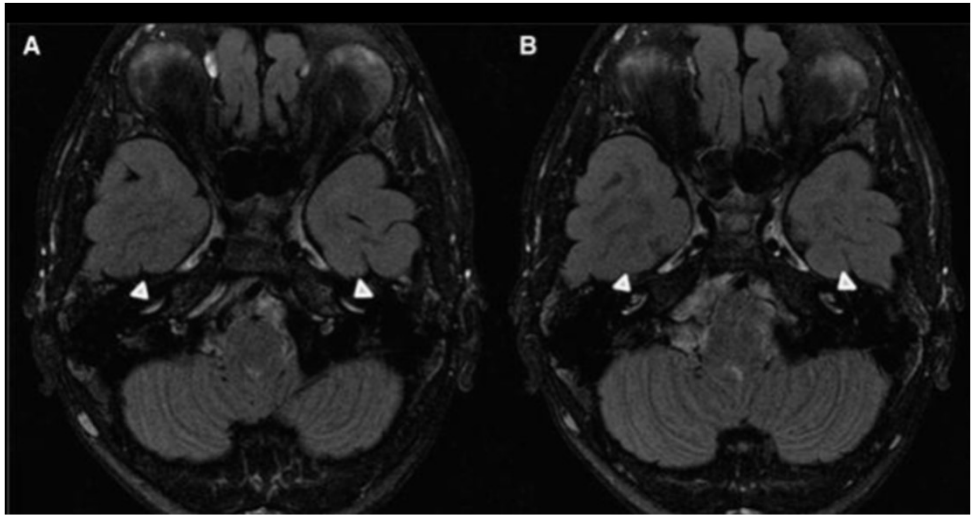

DOI: 10.1177/0194599811402296

Molecular genetic testing for mutations in the NLRP3 gene may confirm the CAPS diagnosis

In France, a twofold increase in molecular genetic examinations was registered between 2005 and 2009, but only in 16% of 821 cases was an NLRP3 mutation confirmed [Cuisset et al. 2011]

Therefore, criteria that may be applied to reduce unnecessary genetic screening were suggested:

≥3 recurrent disease episodes

age at disease onset <20 years

elevated C-reactive protein (CRP) level (or any other inflammation marker)

urticaria

fever

https://doi.org/10.1177/1759720X13502629

Before the identification of the underlying pathological mechanisms for CAPS and the development of targeted IL-1 inhibition, therapeutic options were scarce

cold avoidance

anti-inflammatory drugs (decreased symptoms but could not change the underlying pathogenesis(IL-1 secretion)):

-nonsteroidal anti-inflammatory drugs (NSAIDs), antirheumatics(methotrexate/MTX),

TNF antagonists

Novel treatments - IL-1 inhibitors:

-anakinra, rilonacept, and canakinumab

https://doi.org/10.1177/1759720X13502629

Anakinra - recombinant form of human IL-1Ra that directly competes with IL-1 for binding to the IL-1 type I receptor, blocking the biological activity of IL-1
Canakinumab - human monoclonal antibody, selectively targets IL-1β
Rilonacept - human dimeric fusion protein, interrupts IL-1 signaling by incorporating components of the IL-1 receptor

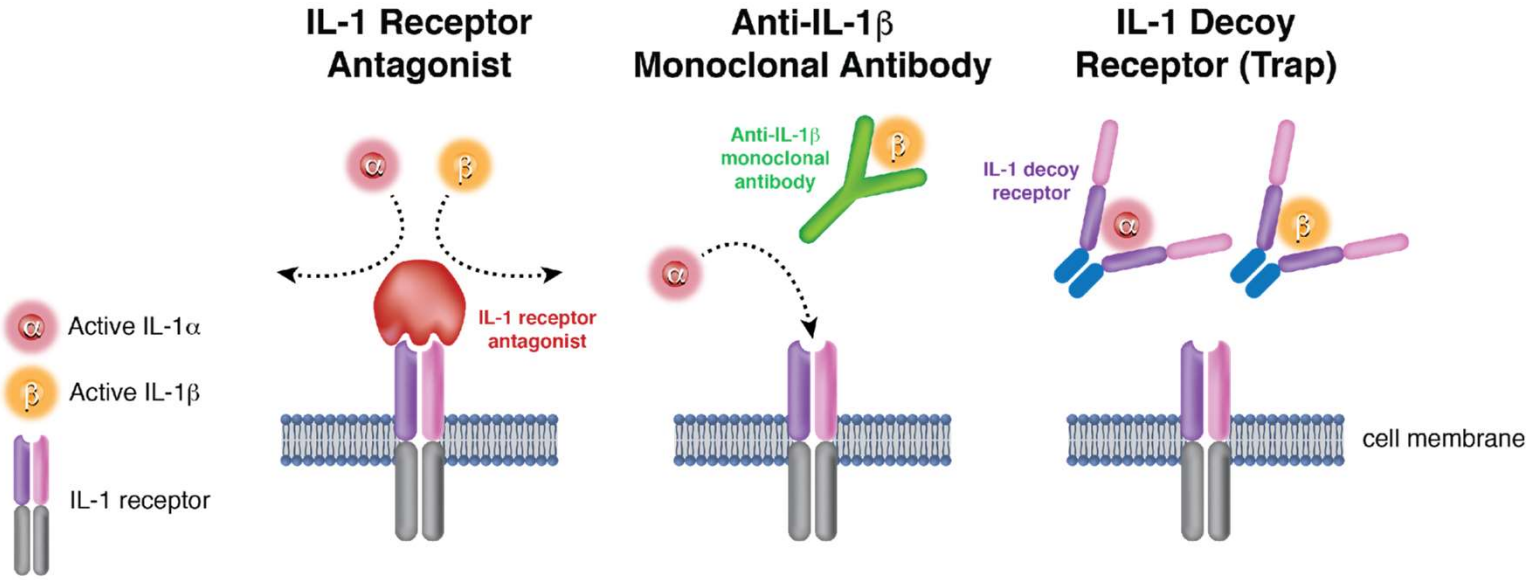

© 2020 Kiniksa Pharmaceuticals | All Rights Reserved

doi: 10.3389/fncel.2015.00018

Canakinumab (Ilaris) - monoclonal antibody against IL-1β. It has been developed using Medarex Inc's (NJ, USA) UltiMab™ technology [Church and McDermott, 2010]

≥15 kg to ≤40 kg	2 mg/kg every 8 weeks	Dose can be increased to 3 mg/kg*
>40 kg	150 mg every 8 weeks	—

Copyright © 2022 Novartis Pharmaceuticals Corporation.

In our patient, we used the standard protocol (150 mg s/c)
Within the next week: less joint pain, no urticaria-like rash, and improvement in hearing
Serum amyloid A levels also went down!

Continuation of canakinumab every 8 weeks
Periods of flare-ups – reduction in the intervals between doses

Date	Serum Amyloid A (N 0-6,4 mg/L)	CRP (N 0-0,5 mg/dL)
22.03.2022	**741 mg/L !!!**	**7,7 mg/dL**
14.04.2022	23,2 mg/L	1,9 mg/dL
04.05.2022	**1000 mg/L !!!**	**7,1 mg/dL**
20.05.2022	12,7 mg/L	2,1 mg/dL

In March 2023, our patient received a living-donor (related:mother) kidney transplant

Simultaneously with the kidney transplant, the patient also underwent a bilateral nephrectomy (due to severe proteinuria >20g per day)

Date	Protein/creatinine (N 0-0,3 mg/mg)
20.12.2021	**27,1 mg/mg**
18.04.2022	**28 mg/mg**
02.02.2023	**20,05 mg/mg**
10.03.2023	**0,37 mg/mg !**
22.03.2023	**0,14 mg/mg !**

Date	Serum Amyloid A (N 0-6,4 mg/L)
08.04.2023	3,81 mg/L
10.07.2023	4,9 mg/L

The initial immunosuppressive therapy:
induction Antithymocyte globulin (ATG)
maintenance Tacrolimus, Mycophenolate mofetil and Prednisolone

The creatinine decreased to **1.8 mg/dl**
No rejection episodes
Therapy with canakinumab continued
No flares of MWS
No severe bacterial or viral infections
No any other adverse events

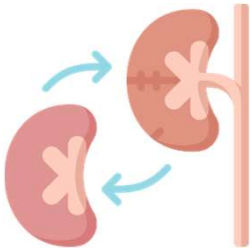

doi: 10.1093/ndtplus/sfr118

Paternal cousin with joint pain:

Test	Result
Blood Creatinine	0,78 mg/dL (N 0,50-1,10 mg/dL)
Urine Protein/creatinine	0.2 mg/mg (N 0-0,3 mg/mg)
CRP	**5,7 mg/dL (N 0-0,5 mg/dL)**
Serum Amyloid A	**872 mg/L (N 0-6,4 mg/L)**

Düzen Laboratuvarlar Grubu

"Uluslararası Kalite Güvencesi"

www.duzen.com.tr

TÜRKAK

GENETİK HASTALIKLAR TANI MERKEZİ

HASTA ADI SOYADI :	[redacted]	**ÖRNEK TİPİ :**	Periferik kan
YAŞ :	26	**KABUL TARİHİ :**	25.05.2022
PROTOKOL NO :	AMG-0994-22	**RAPOR TARİHİ :**	14.06.2022
ÖN TANI :	Aile öyküsü	**İSTENEN TETKİK :**	*CIAS1* geni mutasyonları
KAYIT NO :	14929110	**GÖNDEREN MERKEZ :**	Ellab MMC

CIAS1 GENİ DİZİ ANALİZİ

Yöntem: Genomik DNA Yeni Nesil Dizi Analizi,SeqPilot yazılımı

İncelenen Bölgeler: *CIAS1 /NLRP3* geni Ekzon 1-9

NCBI Genomik Referans Dizi: NG_007509.2, NM_004895.4

Hastalığa neden olan Mutasyon/lar:

p.T350M (c.1049C>T) (rs151344629) mutasyonu heterozigot olarak saptanmıştır.
Kodlayan dizinin 1049. pozisyonundaki sitozin nükleotidi timine dönüşmüştür. Bu değişim proteinin 350. pozisyonunda treonin aminoasidi yerine metionin amino asidi oluşumuna neden olmaktadır. **ClinVar** veritabanında belirtilen rs numarası *'Pathogenic'* olarak kayıtlıdır. Model analiz programı; bu değişimin klinik etkisi hakkında öngörüde bulunmaktadır. (Varsome: *Likely Pathogenic*), (Franklin: *Pathogenic*)

***GENETİK DANIŞMA VE AİLE ÇALIŞMASI ÖNERİLİR.**

Gözlenen diğer mutasyon/polimorfizmler arka sayfada listelenmiştir.

p.T350M (c.1049C>T) (rs151344629) mutation detected as heterozygous

NDT Plus. 2011 Dec; 4(6): 404–405.
doi: 10.1093/ndtplus/sfr118
PMCID: PMC4421672
PMID: 25984207

Successful renal transplantation in Muckle–Wells syndrome treated with anti-IL-1β-monoclonal antibody

Birgit Kortus-Götze and Joachim Hoyer

CASE REPORT article
Front. Immunol., 16 April 2019
Sec. Autoimmune and Autoinflammatory Disorders
Volume 10 - 2019 | https://doi.org/10.3389/fimmu.2019.00802

Muckle-Wells Syndrome Across Four Generations in One Czech Family: Natural Course of the Disease

Šárka Fingerhutová[1], Jana Fráňová[2], Eva Hlaváčková[3], Eva Jančová[4], Leona Procházková[5], Kamila Beránková[6], Markéta Tesařová[6], Eva Honsová[7] and Pavla Doležalová[1*]

Thank you for your attention